

# Effects of paramagnetic contrast agents on the gallbladder volume

Hasan Nazaroğlu, Kaan Meriç, Cihan Akgül Özmen, Yaşar Bükte, Hatice Öztürkmen Akay

## PURPOSE

Iodinated contrast agents lead to contraction of the gallbladder. The purpose of this prospective study was to investigate whether the paramagnetic contrast agents used for magnetic resonance imaging (MRI) cause volume changes in gallbladder or not.

## MATERIALS AND METHODS

The gallbladder volume changes were evaluated by ultrasound just before and 15 minutes after the imaging procedure in 10 patients without any paramagnetic contrast agent administration and 36 patients in whom paramagnetic contrast agents were administered during MRI. Gallbladder volume measurements before and 15 minutes after MRI were compared with each other.

## RESULTS

The mean pre- and post-procedural gallbladder volumes in patients on paramagnetic contrast agents were  $30.2 \pm 19.3$  cm<sup>3</sup> and  $27.8 \pm 13.5$  cm<sup>3</sup>, respectively. They were  $31.8 \pm 15.0$  cm<sup>3</sup> and  $29.5 \pm 9.3$  cm<sup>3</sup>, respectively, in patients who were not administered any paramagnetic contrast agent. There were no statistically significant difference between groups, regarding pre- and post-MRI gallbladder volumes.

## CONCLUSION

MRI, with or without paramagnetic contrast agents, does not lead to gallbladder volume contraction. In that regard, there appears to be no need to avoid ultrasound aimed to evaluate the gallbladder after MRI examinations.

*Key words:* • gallbladder • ultrasound • contrast media • magnetic resonance imaging

**M**agnetic resonance imaging (MRI) with or without paramagnetic contrast agents is a frequently used diagnostic tool. After pathologic findings such as a tumoral mass are diagnosed with the use of MRI, abdominal ultrasound may be warranted for further investigation of the patient. Consumption of food, particularly of a fatty nature, stimulates gallbladder contraction (1). Also, intravenous injection of nonionic, iodinated contrast media or ingestion of water or a dilute solution of contrast medium for various radiological examinations results in contraction of the gallbladder (2–5). The contracted gallbladder appears thick walled and may obscure luminal or wall abnormalities. Therefore, examination of the gallbladder should be performed after a minimum of 4 hours of fasting (1). If MRI examination itself or administration of paramagnetic contrast agents results in contraction of the gallbladder, abdominal ultrasonography performed following the MRI examination would not be suitable. We could not find any publication in the literature related to the effects of MRI examination or paramagnetic contrast agents, which are used during MRI, on gallbladder contraction.

The purpose of this prospective study was to investigate whether the paramagnetic contrast agents used for MRI cause volume changes in gallbladder or not.

## Materials and methods

The entire study group included 46 patients who were evaluated by MRI due to various indications. Group A consisted of 36 patients to whom paramagnetic contrast agents were administered during MRI and Group B (control group) consisted of 10 patients without contrast agent administration. The mean age of patients was 41 years (range, 19–73). Twenty-two (48%) of them were women and 24 (52%) were men. All examinations were performed after an overnight fasting period of 8–10 hours. Only patients who had a normal gallbladder on ultrasound examination were included in the study. Patients with any pathologic finding of gallbladder on ultrasound were not included. Oral informed consent was obtained from all participants.

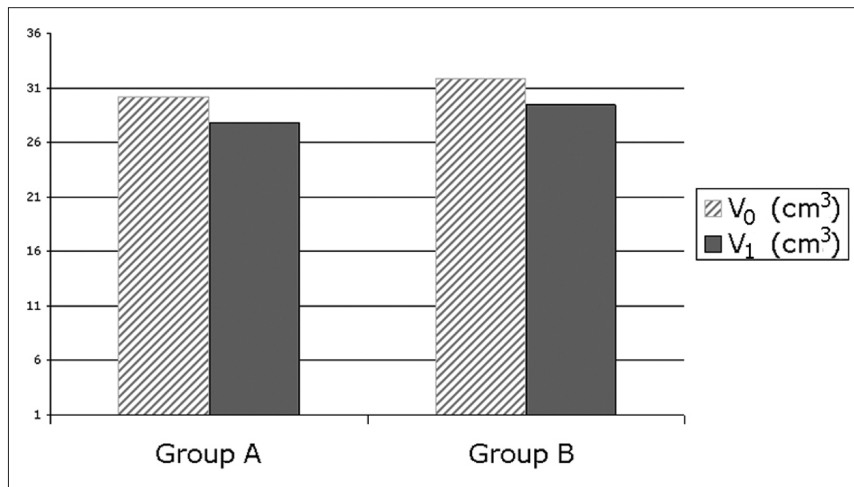
Gallbladder volumes were measured before and 15 minutes after MRI by the same radiologist (K.M.) with ultrasound (Toshiba SSH-140A, Tokyo, Japan). Gallbladder volume was measured sonographically by using a 3.75 MHz convex probe. The average of two measurements was used to calculate the volume by using the ellipsoid formula (length x width x depth x 0.52).

Subjects were not eligible if they were younger than 18 years old or had a history of biliary disease, previous gastric surgery or vagotomy, diabetes mellitus, intraabdominal sepsis, gastrointestinal malignancy, or gallstones. Patients having a gallbladder abnormality on sono-

From the Department of Radiology (H.N. ✉ [hnazarog@dicle.edu.tr](mailto:hnazarog@dicle.edu.tr)), Dicle University Faculty of Medicine, Diyarbakir, Turkey.

Received 5 September 2007; revision requested 20 March 2008; revision received 20 May 2009; accepted 10 August 2009.

Published online 2 November 2009  
DOI 10.4261/1305-3825.DIR.1353-07.2



**Figure.** Chart of gallbladder volume changes in Group A (with paramagnetic contrast agent administration) and Group B (without paramagnetic contrast agent administration).

graphic examination were excluded from the study.

Three types of paramagnetic contrast agents (gadodiamide [Omniscan; Amersham Health, Cork, Ireland], gadopentetate dimeglumine [Magnevist; Schering AG, Berlin, Germany], and gadoteric acid [Dotarem; Guerbet, Paris, France]) were administered to patients in Group A during the MRI. The paired-t test was used for the comparison of the pre- and post-MRI gallbladder volumes in Group A. Wilcoxon test was used to compare gallbladder volumes in Group B.

### Results

Pre- and post-MRI gallbladder volumes of the groups are depicted in Figure. The mean pre- and post-MRI gallbladder volumes in patients of Group A were  $30.2 \pm 19.3 \text{ cm}^3$  and  $27.8 \pm 13.5 \text{ cm}^3$ , respectively. They were  $31.8 \pm 15.0 \text{ cm}^3$  and  $29.5 \pm 9.3 \text{ cm}^3$  in patients of Group B. There were no statistically significant differences between pre- and post-MRI gallbladder volumes in either group.

### Discussion

Ultrasound is one of the first investigation methods for evaluating abdominal complaints. However, it is not suitable for the adult cranium and spine. MRI, with or without paramagnetic contrast agents, is the most useful investigation method for these regions. After pathologic findings such as a tumoral mass diagnosed by MRI, abdominal ultrasound may be warranted to investigate a primary focus. Gallblad-

der contraction may lead to difficulties in its imaging evaluation.

Gallbladder motility parameters (emptying and filling) are controlled by both neural and endocrine mechanisms. This control is a complex process involving the enteric and autonomic nervous systems as well as the interplay between several hormones. Endocrine factors include both intrinsic and extrinsic hormones and/or peptides which act as hormones (6). In humans, eating normally causes the gallbladder to empty up to 75% of its contents (7). Gallbladder emptying in response to meal ingestion is mediated predominantly by cholecystokinin and vagal cholinergic pathways (8). Intestinal release of cholecystokinin follows the ingestion of food, with the most potent stimuli being protein- and fat-rich foods (9). Cholecystokinin is the primary stimulus for gallbladder contraction and for reciprocal relaxation of the sphincter of Oddi. Acetylcholine is the principal neural mediator of gallbladder contraction and sphincter of Oddi relaxation (7).

Several medications improve gallbladder motility, by influencing various pathways. Motilin-analogue erythromycin, intravenous administration of a mixture of essential and non-essential amino acids, cholinomimetic drugs, such as bethanecol and prostigmine, stimulate gallbladder contraction (10, 11). Likewise, intravenous injection of nonionic iodinated contrast media or ingestion of water or a dilute solution of contrast medium for various radiological examinations

results in the contraction of the gallbladder (2–5).

In our study, we investigated whether the paramagnetic contrast agents used for MRI cause volume changes in the gallbladder or not. Because paramagnetic contrast agents have similar chemical characteristics, we did not compare the impact of the available three contrast agents individually in the gallbladder contraction rate which may be the subject of another study. We found that performing MRI, with or without paramagnetic contrast agents, does not lead to a significant change of gallbladder volume. Therefore, we conclude that there is no need to avoid ultrasound after MRI, when it is necessary to evaluate the gallbladder.

### References

1. Khalili K, Wilson SR. The biliary tree and gallbladder. In: Rumack CM, Wilson SR, Charboneau JW, eds. Diagnostic ultrasound. 3rd ed. St Louis: Elsevier-Mosby, 2005; 171–212.
2. Nazaroğlu H, Akgül C, Bukte Y, Bilici A, Simsek M. Volume changes in the gallbladder in association with various radiologic examinations. *J Clin Ultrasound* 2005; 33:214–217.
3. Khan O, Naipaul R, Rampaul RS, et al. Contrast material and gallbladder kinetics: implications for same day sonography after intravenous pyelography or CT scanning. *J Ultrasound Med* 1999; 18:763–767.
4. Khan O, Naipaul R, Maharaj P. Is same-day sonography of the gallbladder feasible after intravenous urography or contrast-enhanced computed tomography? *J Ultrasound Med* 2002; 21:977–981.
5. Starinsky R, Alon Z. Gallbladder size: is it affected by the oral intake of water or dilute contrast medium? *J Ultrasound Med* 1994; 13:435–438.
6. Jazrawi RP. Measurement of gallbladder motor functions: an overview. *Dig Liver Dis* 2003; 35 Suppl 3:S51–55.
7. Shaffer EA. Control of gall-bladder motor function. *Aliment Pharmacol Ther* 2000; 14 Suppl 2:2–8.
8. Hoentjen F, Hopman WP, Jansen JB. Effect of circulating peptide YY on gallbladder emptying in humans. *Scand J Gastroenterol* 2001; 36:1086–1091.
9. West SD, Mercer DW. Cholecystokinin-induced gastroprotection: a review of current protective mechanisms. *Dig Dis Sci* 2004; 49:361–369.
10. vanBerge-Henegouwen GP, Venneman NG, van Erpecum KJ, Portincasa P. Drugs affecting biliary lipid secretion and gallbladder motility: their potential role in gallstone treatment and prevention. *Curr Drug Targets Immune Endocr Metabol Disord* 2005; 5:185–191.
11. Marzio L. Factors affecting gallbladder motility: drugs. *Dig Liver Dis* 2003; 35 Suppl 3:S17–19.