

Rare CT feature in a COVID-19 patient: cavitation

Zhifeng Xu ^{ID}
 Aizhen Pan ^{ID}
 Huiling Zhou ^{ID}

From the Departments of Radiology (Z.X., A.P. ✉ Pazhen2121@126.com) and Infection (H.Z.), First People's Hospital of Foshan, China.

Dear Editor,

Coronavirus disease 2019 (COVID-19) caused by severe acute respiratory syndrome coronavirus 2 (SARS-CoV-2) infection emerged in December 2019 in Wuhan, China, and has spread globally, involving more than 200 countries (1). As of 4 April 2020, COVID-19 has caused 1 017 549 confirmed cases including 53 055 deaths in the whole world. China's experience revealed that lung CT could play a vital role in the early detection and management of COVID-19. However, it is worth emphasizing that to confirm SARS-CoV-2 infection, reverse-transcription polymerase chain reaction (RT-PCR) test is required. A study reported that the sensitivity of lung CT in suggesting COVID-19 was 97% based on positive RT-PCR results, and 75% patients with negative RT-PCR results showed positive lung CT findings (2). Lung CT findings were included as important evidence for clinical diagnosis of COVID-19 in Hubei province. Therefore, identification of the key CT features of COVID-19 is very helpful for accurate screening and diagnosis.

Previous reports and our experience revealed that COVID-19 involves multiple lobes of the lung, with typical CT findings including ground glass opacities (GGO), opacities with a rounded morphology, consolidation with GGO, and crazy-paving pattern. In addition, enlarged mediastinal lymph nodes and pleural fluid have been reported as rare CT features in some severe patients (3–5). However, as far as we know, no necrotic cavity has been reported

to date. Therefore, COVID-19 could be excluded if cavitory lesions were present, and this had been our mantra in the diagnosis of COVID-19 until a case appeared.

Here, we share the details of that case as follows. A 27-year-old man was admitted to hospital with fever and cough with sputum for one day. The patient returned to Foshan from Wuhan on January 21, then developed a fever on January 23, with a temperature of 38.5°C, WBC of $5.02 \times 10^9/L$ and lymphocyte count of $1.01 \times 10^9/L$. He was isolated as a suspected case of COVID-19. Lung CT showed some small nodules and a cavitation in the apical segment of the lower lobe of the right lung (Fig. a). Pulmonary tuberculosis was not excluded because of typical site of disease (dorsal segment) and similar CT findings, but most importantly, no cavitory lesion was reported in patients with COVID-19. On January 25, he was confirmed to have COVID-19, with a positive RT-PCR result. At that moment, we believed that tuberculosis still could not be excluded, because some patients with RT-PCR-confirmed COVID-19 have normal lung CT. Additionally, the current knowledge that "necrotic cavity can rule out COVID-19" constantly stimulated our thinking. After symptomatic and anti-infective treatments (arbidol, 0.2 mg, tid for 14 days; moxifloxacin, 0.4 mg IV drip, qd for 25 days, kaletra, 2 tablets, per oral, bid for 8 days) and atomized inhalation of interferon (30 µg bid, for 8 days) the symptoms gradually improved. After 5 days of treatment, lung CT showed that the cavity was enlarged, but the surrounding lesions were resorbed (Fig. b). At the same time, T-SPOT.TB of tuberculosis, RT-PCR of fungi, respiratory tract viruses (RTV), influenza A and influenza B, and sputum and blood culture of bacteria were all tested and showed negative results. Therefore, the patient was mainly treated with antivirals (arbidol, kaletra and moxifloxacin) during the remainder of the treatment. On February 4, lung CT showed significantly reduced cavity and RT-PCR became negative (Fig. c). The patient was successfully cured and discharged according to the diagnostic criteria in the most recently published national guideline for COVID-19 pneumonia (6). A control CT performed two weeks later showed complete disappearance of the lung cavity (Fig. d).

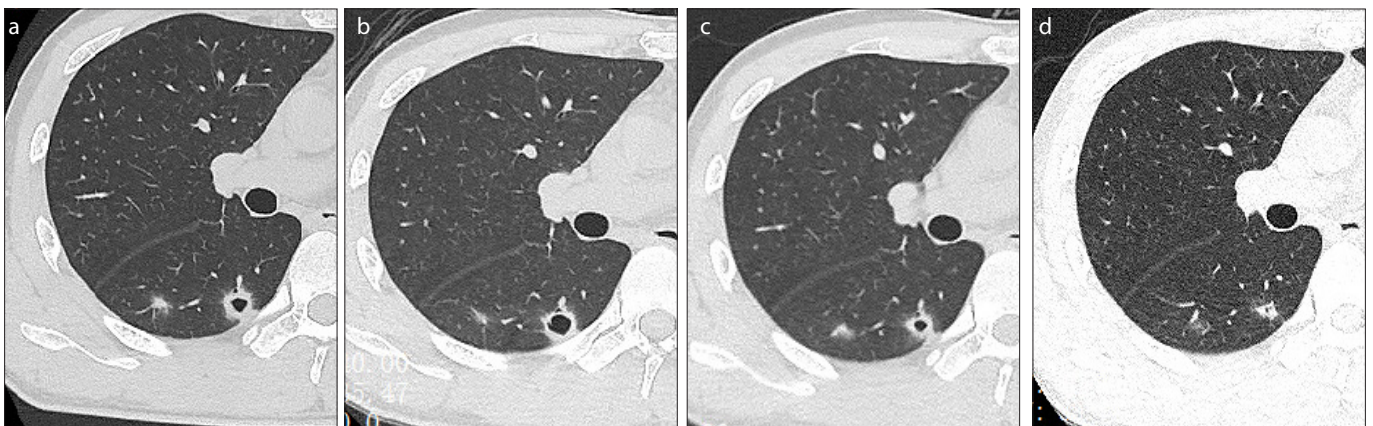


Figure. a–d. Imaging changes in a 27-year-old patient with COVID-19 during the course of treatment. Axial lung CT image (a) taken on January 24, 2020 showed some small nodules and a cavitation in the dorsal segment of the right lobe. Axial lung CT image (b) taken on January 28, 2020 showed the lesions were resorbed, but with enlarged cavity. Axial lung CT image (c) taken on February 4, 2020 showed the lesions were more resorbed and cavity was reduced. Axial lung CT image (d) taken on February 19, 2020 showed the cavity disappear.

Our findings indicate that as a new CT feature, the cavity lesion is an important supplement to the current image features reported on COVID-19. Although it is rare and the specific pathological basis is still unknown, it can help deepen the understanding of the disease and even change the diagnostic thinking based on the CT features.

Conflict of interest disclosure

The authors declared no conflicts of interest.

References

1. Guan WJ, Ni ZY, Hu Y, et al. Clinical characteristics of coronavirus disease 2019 in China. *NEJM* 2020; 382:1708–1720. [\[Crossref\]](#)
2. Ai T, Yang Z, Hou H, et al. Correlation of chest CT and RT-PCR testing in coronavirus disease 2019 (COVID-19) in China: a report of 1014 cases. *Radiology* 2020; 200642. [\[Crossref\]](#)
3. Chung M, Bernheim A, Mei X, et al. CT imaging features of 2019 novel coronavirus (2019-nCoV). *Radiology* 2020; 295:202–207. [\[Crossref\]](#)
4. Lei J, Li J, Li X, Qi X. CT imaging of the 2019 novel coronavirus (2019-nCoV) pneumonia. *Radiology* 2020; 295:18. [\[Crossref\]](#)
5. Wu W, Xu Z, Jin YB, Pan A. Key points of clinical and ct imaging features of 2019 novel coronavirus (2019-nCoV) imported pneumonia based on 21 cases analysis. *MedRxiv* 2020, Mar 6. [Published online] [\[Crossref\]](#)
6. General Office of National Health Committee. Office of State Administration of Traditional Chinese Medicine. Notice on the issuance of a program for the diagnosis and treatment of novel coronavirus (2019-nCoV) infected pneumonia (trial 7th edition) (2020-Mar-05).

Received 03 April 2020; revision requested 06 April 2020; last revision received 13 April 2020; accepted 15 April 2020.

Published online 20 May 2020.

DOI 10.5152/dir.2020.20181

You may cite this article as: Xu Z, Pan A, Zhou H. A new and rare CT feature in a patient with COVID-19. *Diagn Interv Radiol* 2020; 26:380–381.