

# Transrectal US-guided seminal vesicle aspiration in the diagnosis of partial ejaculatory duct obstruction

Gülgün Engin

## ABSTRACT

There has been recent interest in techniques for diagnosing ejaculatory duct obstruction (EDO), especially when the partial form of the disease is suspected clinically. Currently, there is no gold standard technique for diagnosing EDO. Transrectal ultrasonography (TRUS), which is the technique used most widely, can overdiagnose EDO. As adjunctive diagnostic techniques, duct chromotubation and seminal vesiculography cannot distinguish patients with partial obstruction from those without EDO. TRUS-guided seminal vesicle aspiration can be used in conjunction with TRUS to confirm the diagnosis pre-operatively, especially in patients with seminal vesicle dilation and a prostatic midline/ejaculatory duct cyst on TRUS. In patients with findings of chronic inflammation, such as ejaculatory duct calcifications and seminal vesicle atrophy/hypoplasia on TRUS, proximal vasal obstruction or functional EDO should be excluded.

*Key words:* • male infertility • ejaculatory ducts • seminal vesicles • transrectal high-intensity focused ultrasound

Recently, there has been increased interest in techniques used to diagnose ejaculatory duct obstruction (EDO). The specificity of diagnostic techniques and their contribution to the choice of treatment are important and controversial topics. Transrectal ultrasonography (TRUS) is the technique used most widely for diagnosing EDO because it is widely available and relatively non-invasive (1, 2). Given its low specificity, however, its use alone has become controversial in the last decade, especially in cases in which the partial form of the disease is suspected clinically (3, 4). Partial EDO, unlike complete or classic EDO with a low ejaculate volume  $\leq 1.5$  mL and azoospermia, has highly variable semen parameters (normal to low ejaculate volume, normal or reduced sperm account, or abnormal sperm motility) (5, 6).

Findings of TRUS suggestive of EDO include dilated seminal vesicles (SVs) (diameter  $>1.5$  cm), vasal ampulla (diameter  $>6$  mm), and ejaculatory ducts (EDs) (diameter  $>2$  mm), especially when associated with a prostatic midline cyst or calcification along the course of the duct or verumontanum (Figs. 1 and 2) (7). Unfortunately, a dilated SV, VA, or ED is not seen in all cases of EDO, and these structures can be dilated in the absence of obstruction in up to 50% of cases (8–10). As is true for SV dilation, the presence of a midline cyst does not assure the diagnosis of EDO, but certainly suggests obstruction in the correct clinical setting (11). Prostate or ED calcifications that result from prior prostatic inflammation are not a reliable indicator of obstruction (10, 12). Jarow (11) found that hyperechoic lesions on TRUS were present in similar proportions of fertile and infertile men. Moreover, it is not clear how prostate inflammation leads to EDO. It is theorized that inflammatory involvement of the EDs themselves leading to stenosis or obstruction could cause a mechanical obstruction, whereas changes in the compliance of the ED walls or of the adjacent prostatic tissue could cause a functional obstruction (8, 13–15).

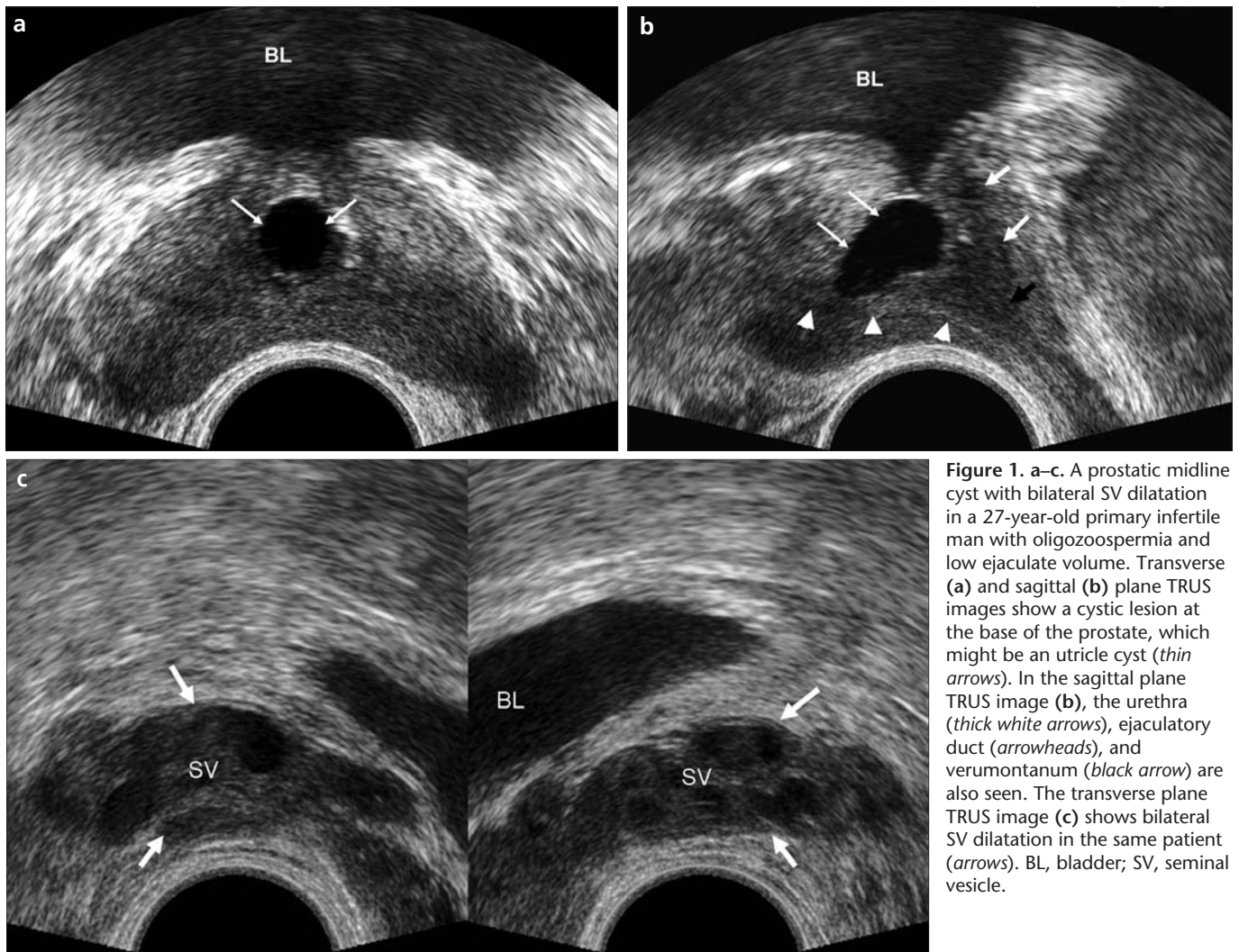
Endorectal or phase array pelvic magnetic resonance imaging (MRI) can depict the pathological changes that can lead to EDO (2, 7). High-soft-tissue contrast, multiplanar capability, the accuracy of localizing lesions, and the characteristics of the cystic lesions in T2-weighted images make MRI an ideal imaging method for evaluating these lesions. However, MRI is not used routinely for the diagnosis of EDO because it is expensive, less available than TRUS, and insensitive to calcifications (7).

In recent years, studies have evaluated the accuracy of TRUS in the diagnosis of EDO. Colpi et al. (3) compared the TRUS findings with seminal tract washout in 112 cases with partial EDO. Obstruction on TRUS was confirmed in only 36.3% of seminal tract washout cases. Consequently, additional tests were recommended to be incorporated into the algorithm for diagnosing EDO, such as TRUS-guided SV aspiration, ductal chromotubation, or seminal vesiculography. Nevertheless,

From the Department of Radiology (✉ [gengin@istanbul.edu.tr](mailto:gengin@istanbul.edu.tr)), İstanbul University İstanbul School of Medicine, İstanbul, Turkey.

Received 20 December 2011; revision requested 31 December 2011; revision received 8 January 2012; accepted 12 January 2012.

Published online 23 May 2012  
DOI 10.4261/1305-3825.DIR.5528-11.1



**Figure 1.** a–c. A prostatic midline cyst with bilateral SV dilatation in a 27-year-old primary infertile man with oligozoospermia and low ejaculate volume. Transverse (a) and sagittal (b) plane TRUS images show a cystic lesion at the base of the prostate, which might be an utricle cyst (*thin arrows*). In the sagittal plane TRUS image (b), the urethra (*thick white arrows*), ejaculatory duct (*arrowheads*), and verumontanum (*black arrow*) are also seen. The transverse plane TRUS image (c) shows bilateral SV dilatation in the same patient (*arrows*). BL, bladder; SV, seminal vesicle.

it is still not clear which technique best predicts a successful outcome after transurethral ED resection (TUR-ED) for the treatment of EDO, especially for partial EDO. Purohit et al. (4) reported that, in 25 patients, obstruction on TRUS could be confirmed in only 52%, 48%, and 36% of patients undergoing vesiculography, SV aspiration, and ductal chromotubation, respectively. Like vasography, both ductal chromotubation and seminal vesiculography cannot distinguish between patients with partial obstruction and those without EDO, because dye and contrast molecules are significantly smaller than sperm (16). TRUS-guided SV aspiration is generally accepted as a potential test for the diagnosis of partial EDO (17).

This review describes the technique of TRUS-guided SV aspiration in the diagnosis of partial EDO, and discusses

its advantages and disadvantages compared to other dynamic diagnostic methods.

#### Technique

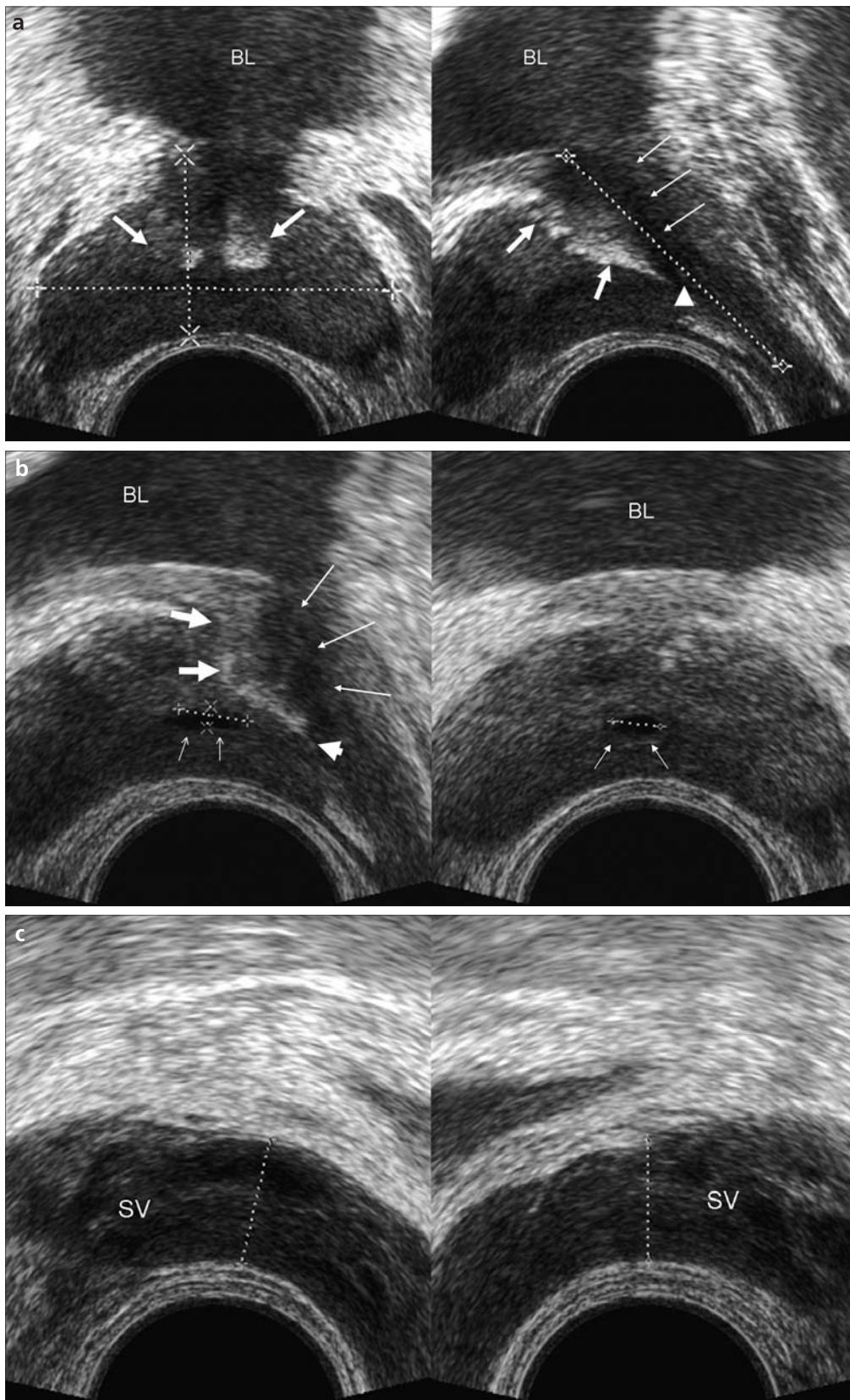
The rationale of TRUS-guided SV aspiration is based on detecting an increased number of sperm in the SV aspirates because of the reflux of sperm into the SV (Fig. 3). In the SV aspiration procedure, with real-time TRUS guidance, each SV is punctured transectally using a 20 G, 25-cm-long echo tip Chiba needle (Matek Medical Equipment Co. Ltd., Ankara, Turkey) within 2 h after ejaculation without local anesthesia (Figs. 4 and 5). Up to 2 mL seminal fluid is aspirated with a 20 mL syringe from each SV and placed on a slide for microscopic examination. The SV aspirates are examined for the presence or absence of sperm with phase-contrast microscopy under

a high-power field ( $\times 400$ ) immediately after aspiration. More than three sperm is considered a positive result for EDO (17).

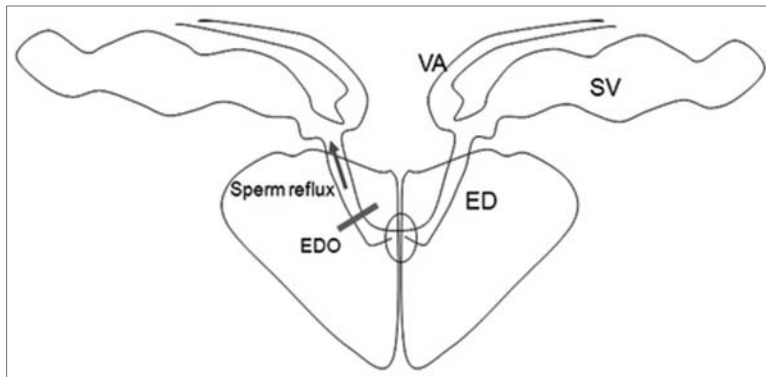
Patients undergoing SV aspiration require a mechanical bowel and antibiotic preparation. Oral antibiotics (ciprofloxacin 500 mg twice daily) and a plain enema are administered before the procedure. The oral antibiotics are started two days before and continued for three days after the procedure. The procedure is performed without local anesthesia.

#### Correlation of TRUS and SV aspiration findings

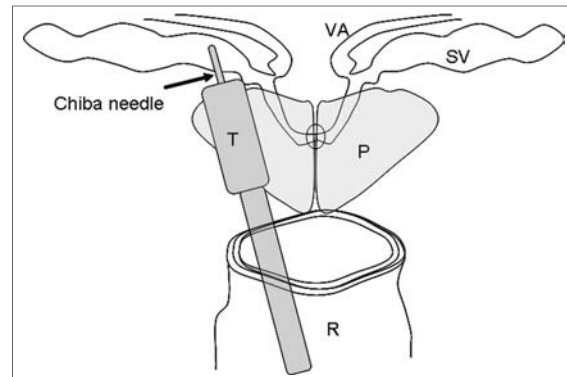
Purohit et al. (4) performed TRUS and three other tests (vesiculography, SV aspiration, and duct chromotubation) in 25 men with EDO. Based on all of the diagnostic tests, only 48% of the patients proceeded to duct resection,



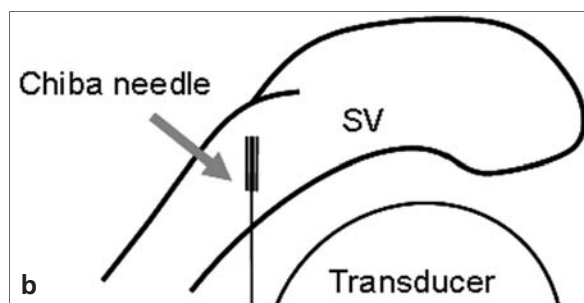
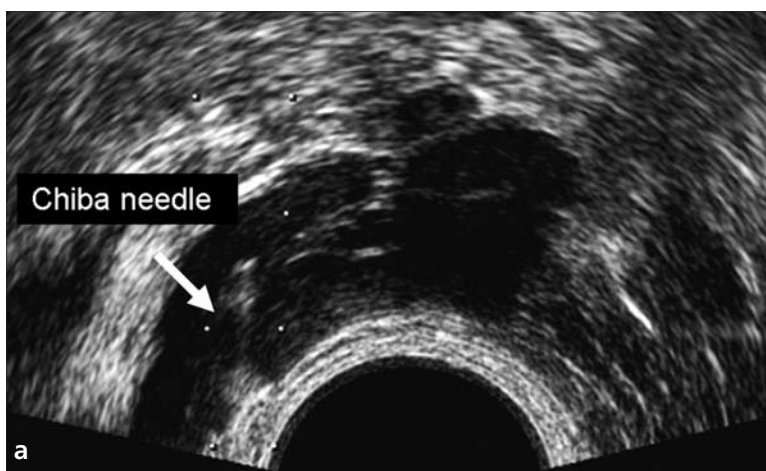
**Figure 2.** a–c. Prostatic calcifications with a prostatic midline cyst and bilateral SV dilatation in a 37-year-old primary infertile man with oligozoospermia and low ejaculate volume. Transverse (right) and sagittal (left) plane TRUS images (a) show coarse prostatic calcifications (*thick arrows*) along the prostatic urethra (*thin arrows*) and at the verumontanum level (*arrowhead*). Transverse (left) and sagittal (right) plane TRUS images (b) show a cystic lesion at the base of the prostate, which might be an utricle cyst or focal dilation of the ejaculatory duct (*small arrows*). The urethra (*long arrows*), verumontanum (*short arrow*), and calcifications (*thick arrows*) are also indicated (b). In the transverse plane TRUS image (c), there is also bilateral SV dilatation in the same patient. BL, bladder; SV, seminal vesicle.



**Figure 3.** Diagram illustrating the reflux of sperm into the seminal vesicle (SV) during ejaculation in patients with ejaculatory duct obstruction (EDO). The coronal view from the middle prostate also shows communication of the contralateral SV, vasal ampulla (VA), and ejaculatory duct (ED).



**Figure 4.** Diagram illustrating transrectal puncture of the seminal vesicle (SV) for aspiration. The coronal view illustrates the use of a TRUS transducer (T) to guide the Chiba needle puncture (arrow) for the SV aspiration. In addition, the contralateral SV, vasal ampulla (VA), prostate gland (P), and rectum (R) are indicated.



**Figure 5. a, b.** TRUS-guided seminal vesicle (SV) aspiration procedure. Transverse plane TRUS image (a) and a diagram (b) showing Chiba needle (arrows) insertion into the SV.

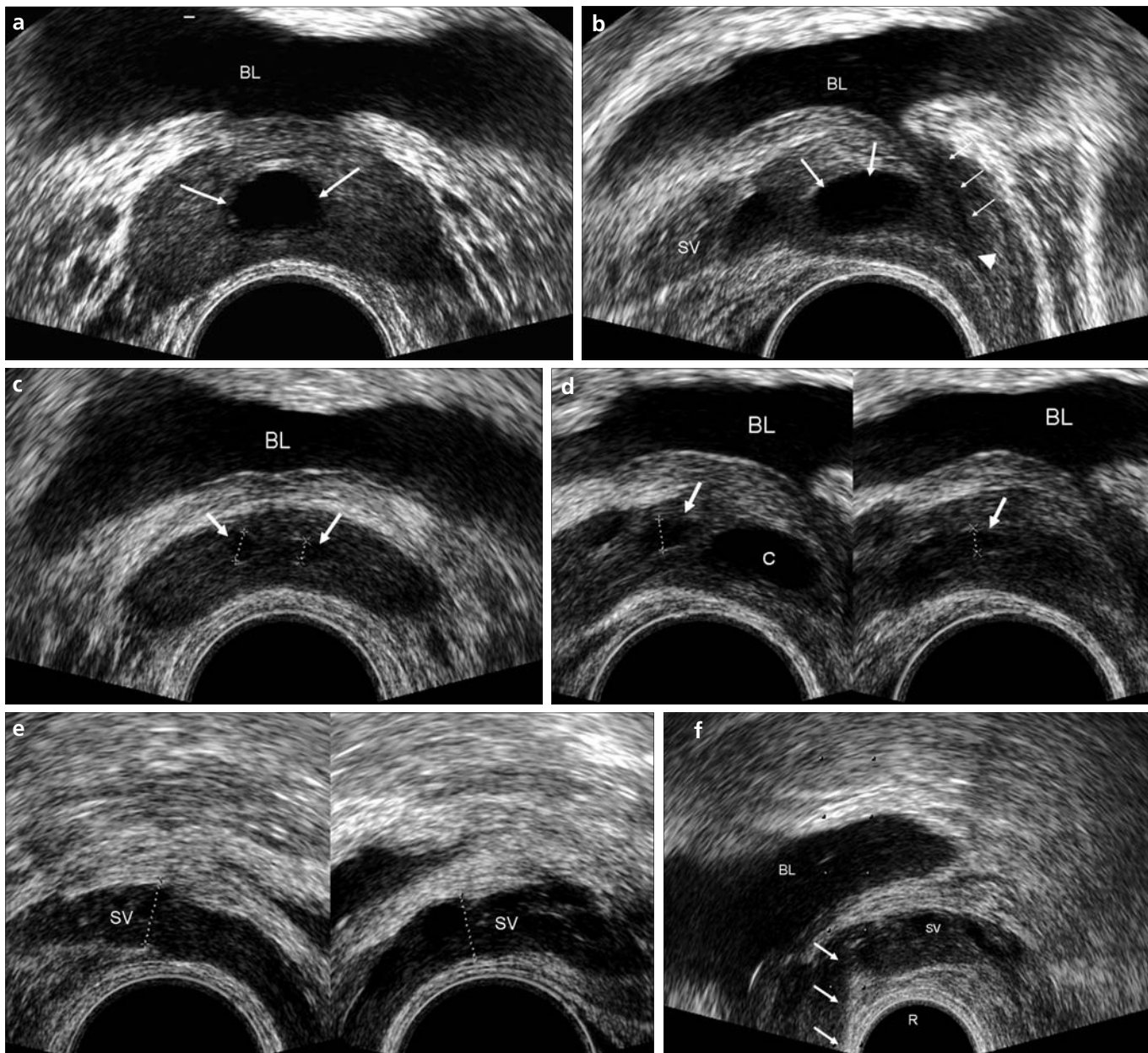
of whom 83% showed a significant improvement in semen analysis parameters or clinical symptoms after the procedure (4).

Similarly, Engin et al. (18) recently confirmed the diagnosis of obstruction on TRUS in only 49.1% of patients with SV aspiration. However, higher rates of aspirate positivity were achieved in patients with SV dilation and prostatic midline/ED cysts (Figs. 6 and 7). Moreover, their stepwise logistic regression analyses showed that the incidence of SV dilation and prostatic midline cyst on TRUS was 131.2 and 2.4 times higher, respectively, in the sperm-positive group. However, the positive SV aspirate rates were very low (19.1%) in patients with chronic inflammatory findings in the prostate, which constituted the largest study group. Moreover, none of the patients with ED calcifications and SV atrophy/hypoplasia (transverse diameter <7 mm) had sperm in their seminal aspirates (Fig. 8).

Coexisting or secondary proximal obstruction is another controversial issue in the diagnosis of EDO. Consequently, the number of recent studies recommending vasography for the diagnosis of EDO is increasing (19, 20). In one such study, Zhao et al. (19) proposed that fine-needle vasography allowed a more comprehensive diagnosis of obstructive azoospermia of EDO than TRUS. In their study, of 37 male patients with pathognomonic TRUS findings, bilateral and unilateral EDO could be confirmed with fine-needle vasography in only five and two patients, respectively. Moreover, fine-needle vasography successfully detected 16 cases of obstruction of the epididymis and proximal vas deferens, seven bilateral vasal multiple obstructions, two unilateral EDO and multiple obstruction of the contralateral vas deferens, and six unilateral vasal multiple obstructions and obstruction of the contralateral

epididymis and proximal vas deferens, which are impossible to diagnose with TRUS.

Paick (21) reported that in 17 of their patients, TRUS showed atrophic SVs. Fifteen of them had a history of pulmonary tuberculosis, and subsequent vasography in the first five patients showed multiple bilateral vasal obstructions. Consequently, they no longer recommend vasography for such patients. Moreover, Kumar (22) stated that most cases of tuberculous infertility are not amenable to surgical correction and these couples are candidates for *in vitro* fertilization. Accordingly, particularly in regions where tuberculosis is endemic, more proximal obstruction should be eliminated rather than SV aspiration in patients with chronic inflammatory findings on TRUS. These couples can also be directed toward *in vitro* fertilization due to the high possibility of multiple obstructions.



**Figure 6.** a–f. A prostatic midline cyst without SV dilation in a 32-year-old primary infertile man with oligozoospermia and low ejaculate volume. Transverse (a) and sagittal (b) plane TRUS images show a cystic lesion at the base of the prostate, which might be an utricle cyst (long arrows). The urethra (thin arrows) and verumontanum (arrowhead) are also indicated (b). In the transverse (c) and sagittal (d) plane TRUS images, bilateral ejaculatory duct dilatation is seen (arrows). In the transverse plane TRUS images (e), the bilateral SV and vasal ampulla (not shown) are normal in the same patient. The transverse plane TRUS image (f) shows a Chiba needle (arrows) inserted into the SV. In the bilateral SV aspirates, 10–15 sperm per high-power microscopic field were found. BL, bladder; C, cyst; SV, seminal vesicle; R, rectum.

### The advantages of SV aspiration

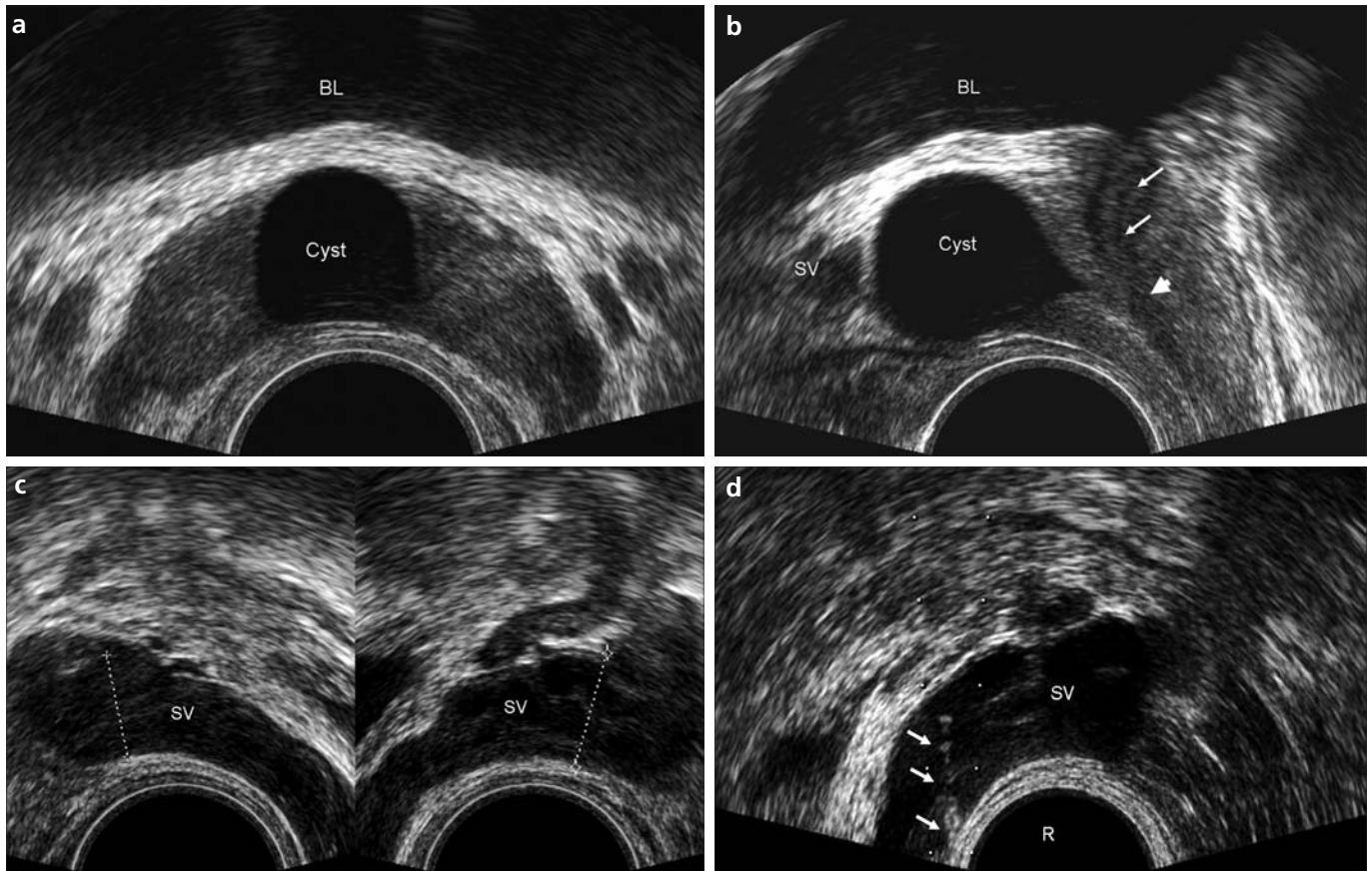
The major advantage of this procedure is that it confirms the presence of intact spermatogenesis and rules out more proximal obstruction, obviating the need for testicular biopsy if the aspirate has sperm (23). In addition, SV aspiration can be performed without anesthesia or X-ray in an office setting, and no dye or contrast medium is necessary, unlike seminal vasography

or duct chromotubation. Moreover, this technique can be used for sperm retrieval in patients with azoospermia (24).

### Disadvantages of SV aspiration

Although superior to other additional techniques, SV aspiration has important limitations. First, it is impossible to localize the obstruction sites. To determine the exact site of EDO, seminal

vesiculography might be performed at the same time SV aspiration. However, as mentioned above, seminal vesiculography cannot diagnose partial EDO, as with vasography. In addition, the injection of contrast medium or dye with exogenously exerted pressure may give false-negative results, because the positive pressure may force the passage of contrast medium through the EDs (16).



**Figure 7. a–d.** A prostatic midline cyst (Müllerian cyst) without SV dilatation in a 26-year-old primary infertile man with oligozoospermia and low ejaculate volume. The transverse (a) and sagittal (b) plane TRUS images show a Müllerian cyst at the base of the prostate. The urethra (*thin arrows*) and verumontanum (*short arrow*) are also indicated (b). In the transverse plane TRUS images (c), the bilateral SVs are seen as normal in the same patient. The transverse plane TRUS image (d) shows a Chiba needle (*arrows*) inserted into the SV. The left and right SV aspirates contained 25–30 sperm and no sperm per high-power microscopic field, respectively. BL, bladder; SV, seminal vesicle; R, rectum.

As an alternative to conventional X-ray vesiculography, ultrasound contrast agents consisting of larger molecules than iodinated contrast agents or dyes can be instilled into the SV for this purpose (25, 26). This procedure can be applied in combination with SV aspiration without additional preparation.

As another important limitation, like vasography, SV aspiration *de facto* cannot sufficiently distinguish functional from anatomic obstruction. The presence of sperm within the SV does not rule out the possibility of a functional obstruction because of emission failure, because these patients may pool sperm within the SV. Indeed, positive aspirate results can be seen in patients with normal TRUS findings (18). Such positive results can be associated with invisible inflammatory ductal scarring/obstruction on TRUS or functional EDO.

#### Additional tests for diagnosing functional EDO

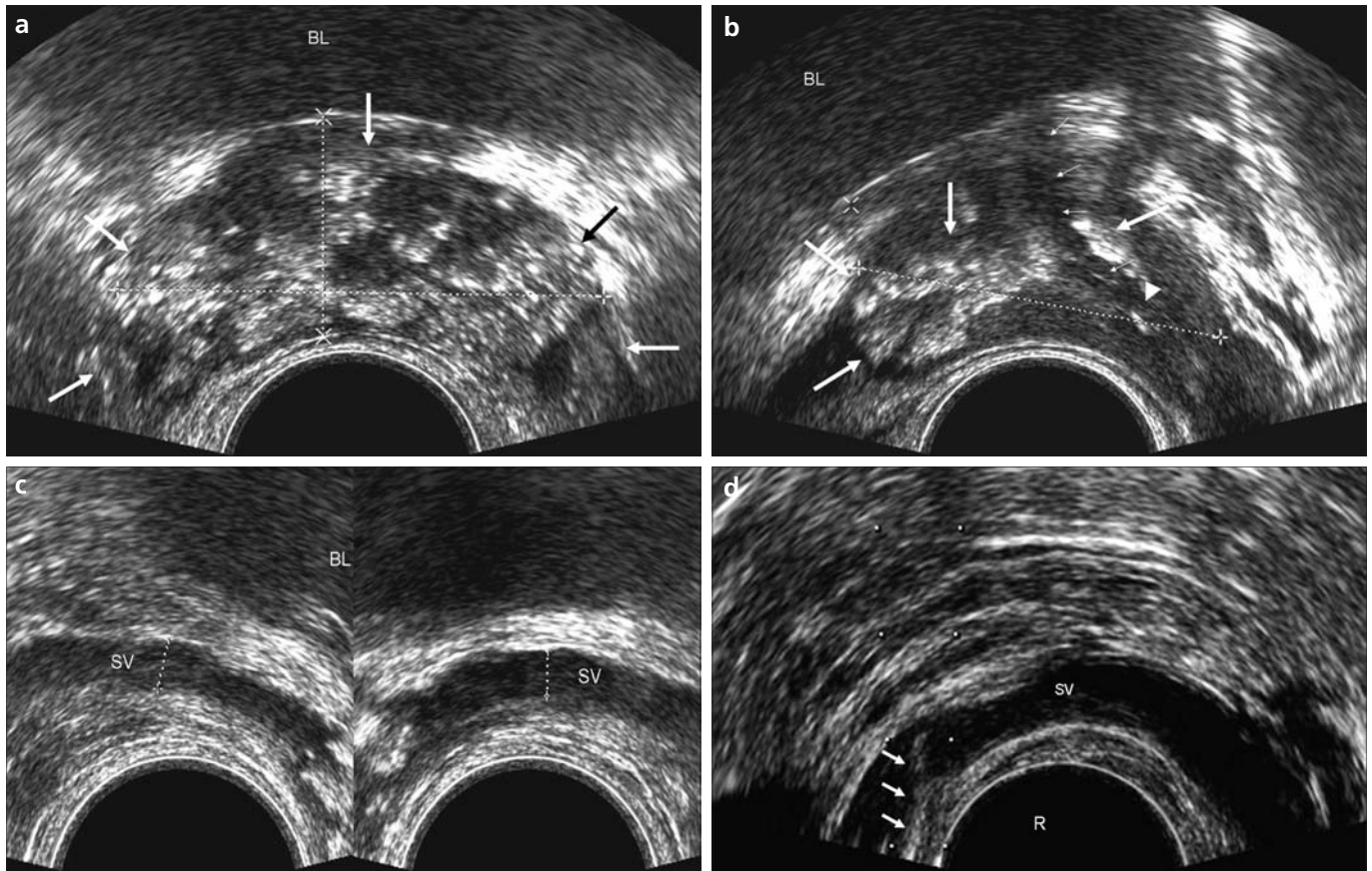
Technetium 99m sulfur colloid SV scintigraphy (27) and a hydraulic test analogous to the Whitaker test defined by Eisenberg et al. (28) are promising for diagnosing functional EDO. Orhan et al. (27) reported that although TRUS initially suggested no physical obstruction, SV scintigraphy revealed that 33% of the patients were obstructed. They suggested that these patients had functional EDO, defined as inefficient emptying of the SV.

Eisenberg et al. (28) investigated the ED opening pressure by using ED manometry in normal men and in patients with EDO. They found that men with clinically suspected EDO had higher ED opening pressures than fertile men, and the ED pressure decreased after TUR-ED. Of the 55% of patients who underwent semen analyses before and after resection, 80% had an increase in ejaculate volume or at least a 100% improvement in the

total motile sperm count (volume × motile fraction × concentration). Although the authors advised performing this method in the routine evaluation of EDO, confirmation of their findings in larger series and longer observations of TUR-ED results are needed.

#### Conclusion

TRUS-guided SV aspiration can be used in conjunction with TRUS to confirm the diagnosis of partial EDO pre-operatively, especially in patients with SV dilatation and a prostatic midline/ED cyst on TRUS. However, in patients with chronic inflammatory findings, such as ED calcifications and SV atrophy/hypoplasia on TRUS, proximal vasal obstruction or functional EDO should be excluded. TRUS-guided seminal vesiculography with an ultrasound contrast agent can be used to determine the exact site of partial EDO. For diagnosing functional EDO, duct manometry is promising.



**Figure 8.** a–d. Chronic prostatitis and atrophy of the SV in a 27-year-old single man with azoospermia and low ejaculate volume. The transverse (a) and sagittal (b) plane TRUS images show diffuse coarse calcifications in the prostate (*long arrows*). The urethra (*thin arrows*) and verumontanum (*arrowhead*) are also indicated (b). In the transverse plane TRUS images (c), bilateral atrophic SVs are seen in the same patient. The transverse plane TRUS image (d) shows a Chiba needle (*arrows*) inserted into the SV. The patient had no sperm in bilateral seminal aspirates. BL, bladder; SV, seminal vesicle; R, rectum.

#### Conflict of interest disclosure

The authors declared no conflicts of interest.

#### References

- Donkol RH. Imaging in male-factor obstructive infertility. *World J Radiol* 2010; 28:172–179.
- Simpson WL, Rausch DR. Imaging of male infertility: pictorial review. *AJR Am J Roentgenol* 2009; 192:98–107.
- Colpi GM, Negri L, Nappi RE, China B. Is transrectal ultrasonography a reliable diagnostic approach in ejaculatory duct sub-obstruction? *Hum Reprod* 1997; 12:2186–2191.
- Purohit RS, Wu DS, Shinohara K, Turek PJ. A prospective comparison of 3 diagnostic methods to evaluate ejaculatory duct obstruction. *J Urol* 2004; 171:232–236.
- Weidner W, Colpi GM, Hargreave TB, Papp GK, Pomerol JM. The EAU working group on male infertility. EAU guidelines on male infertility. *Eur Urol* 2002; 42:313–322.
- Smith JF, Walsh TJ, Turek PJ. Ejaculatory duct obstruction. *Urol Clin North Am* 2008; 35:221–227.
- Engin G, Kadioglu A, Orhan I, Akdol S, Rozanes I. Transrectal US and endorectal MR imaging in partial and complete obstruction of the seminal duct system (a comparative study). *Acta Radiol* 2000; 41:288–295.
- Fisch H, Lambert SM, Goluboff ET. Management of ejaculatory duct obstruction: etiology, diagnosis, and treatment. *World J Urol* 2006; 24:604–610.
- Littrup PJ, Lee F, McLeary RD, Wu D, Lee A, Kumasaka GH. Transrectal US of the seminal vesicles and ejaculatory ducts: clinical correlation. *Radiology* 1988; 68:625–628.
- Wessels EC, Ohori M, Grantmyre JE, et al. The prevalence of cystic dilatation of the ejaculatory ducts detected by transrectal ultrasound (TRUS) in a self-referred (screening) group of men (abstract 973). *J Urol* 1992; 147:456A.
- Jarow JP. Transrectal ultrasonography of infertile men. *Fertil Steril* 1993; 60:1035–1039.
- Carter SS, Shinohara K, Lipshultz LI. Transrectal ultrasonography in disorders of the seminal vesicles and ejaculatory ducts. *Urol Clin North Am* 1989; 16:773–790.
- Pryor JP, Hendry WF. Ejaculatory duct obstruction in subfertile males: analysis of 87 patients. *Fertil Steril* 1991; 56:725–730.
- Goldwasser BZ, Weinerth JL, Carson CC 3rd. Ejaculatory duct obstruction: the case for aggressive diagnosis and treatment. *J Urol* 1985; 134:964–966.
- Worischek JH, Parra RO. Transrectal ultrasonography in the evaluation of men with low volume azoospermia. *J Urol* 1993; 149:1341–1344.
- Jarow JP. Editorial comment for “A prospective comparison of 3 diagnostic methods to evaluate ejaculatory duct obstruction” authors: Purohit RS, Wu DS, Shinohara K, Turek PJ. *J Urol* 2004; 171:232–236.
- Jarow JP. Seminal vesicle aspiration in the management of patients with ejaculatory duct obstruction. *J Urol* 1994; 152:899–901.
- Engin G, Celtik M, Sanli O, Aytac O, Muradov Z, Kadioglu A. Comparison of transrectal ultrasonography and transrectal ultrasonography-guided seminal vesicle aspiration in the diagnosis of the ejaculatory duct obstruction. *Fertil Steril* 2009; 92:964–970.
- Zhao LY, Tu XA, Xiang Y, Sun XZ, Deng CH. Was fine-needle vasography an obsolete diagnostic method to evaluate ejaculatory duct obstruction? Report of 37 cases. *Urol Int* 2010; 85:186–193.

20. Xu B, Niu X, Wang Z, et al. Novel methods for the diagnosis and treatment of ejaculatory duct obstruction. *BJU Int* 2011; 108:263–266.
21. Paick JS. Transurethral resection of the ejaculatory duct. *Int J Urol* 2000; 7:42–47.
22. Kumar R. Reproductive tract tuberculosis and male infertility. *Indian J Urol* 2008; 24:392–395.
23. Jarow JP. Transrectal ultrasonography in the diagnosis and management of ejaculatory duct obstruction. *J Androl* 1996; 17:467–472.
24. Orhan I, Onur R, Cayan S, et al. Seminal vesicle sperm aspiration in the diagnosis of ejaculatory duct obstruction. *BJU Int* 1999; 84:1050–1053.
25. Killi R, Pourbagher A, Semerci B. Transrectal ultrasonography-guided echo-enhanced seminal vesiculography. *BJU Int* 1999; 85:521–523.
26. Cosgrove DO, Kiely P, Williamson R, Blomley MJK, Eckersley RJ. Ultrasonographic contrast media in the urinary tract. *BJU Int* 2000; 86:11–17.
27. Orhan I, Duksal I, Onur R, et al. Technetium Tc 99m sulphur colloid seminal vesicle scintigraphy: a novel approach on the diagnosis of the ejaculatory duct obstruction. *Urology* 2008; 71:672–676.
28. Eisenberg ML, Walsh TJ, Garcia MM, Shinohara K, Turek PJ. Ejaculatory duct manometry in normal men and in patients with ejaculatory duct obstruction. *J Urology* 2008; 180:255–260.