



Effectiveness of balloon angioplasty under intravascular ultrasound guidance in calcified below-the-knee tibial arteries

Muhammed Said Beşler¹

Asiye Sözeri²

Murat Canyığıt³

¹Necip Fazıl City Hospital, Clinic of Radiology, Kahramanmaraş, Türkiye

²University of Health Sciences Türkiye, Ankara Bilkent City Hospital, Clinic of Radiology, Ankara, Türkiye

³Ankara Yıldırım Beyazıt University Faculty of Medicine, Department of Radiology, Ankara, Türkiye

PURPOSE

This study aimed to assess the optimal balloon diameter for intravascular ultrasound (IVUS)-guided balloon angioplasty in calcified below-the-knee (BTK) tibial artery lesions.

METHODS

Between February 2024 and April 2024, a retrospective review was conducted on 17 patients with Rutherford category 4-6 severely calcified tibial arteries with >70% stenosis, treated with IVUS-guided balloon angioplasty. Sequentially, 3 mm and then 3.5 mm diameter balloons were inflated. The minimum lumen diameter and area were measured before and after the procedure in the proximal, mid, and distal segments of the tibial arteries. One- and three-month follow-ups were conducted using Doppler ultrasound.

RESULTS

Significant increases in lumen diameter ($P < 0.001$ for all) and lumen area ($P < 0.001$, $P = 0.003$, $P = 0.002$, respectively) were observed in the proximal, mid, and distal segments of the BTK arteries following IVUS-guided 3.5 mm balloon angioplasty. Ultra-low iodinated contrast media was used [median 2 mL (range, 1–4 mL)]. Lumen area increase ratios were similar among the proximal, mid, and distal segments ($P = 0.905$). No target vessel revascularization, major amputation, or mortality was observed during follow-up. Wound healing was seen in 62.5% of the cases with foot ulcers.

CONCLUSION

In the treatment of calcified BTK tibial arteries, a gradual balloon diameter increase up to 3.5 mm in IVUS-guided balloon angioplasty is safe and effective.

CLINICAL SIGNIFICANCE

Gradual balloon diameter increase up to 3.5 mm under IVUS guidance in calcified BTK lesions demonstrates significant potential. It enables ultra-low contrast usage, provides low complication rates, and achieves high patency and limb salvage, along with satisfactory wound healing in the short term.

KEYWORDS

Intravascular ultrasound, below-the-knee, tibial artery, calcified, ultra-low contrast, balloon angioplasty

Corresponding author: Muhammed Said Beşler

E-mail: msbesler@gmail.com

Received 09 September 2024; revision requested 17 October 2024; accepted 23 November 2024.



Epub: 09.12.2024

Publication date: xx.xx.2024

DOI: 10.4274/dir.2024.243022

Peripheral artery disease affects >200 million people globally.¹ The incidence of chronic limb-threatening ischemia, the severe stage of the disease, is approximately 0.3% and can result in high rates of limb loss and mortality.² In the treatment of below-the-knee (BTK) lesions, which are commonly seen in chronic limb-threatening ischemia cases, the primary goals are wound healing, pain relief, and limb salvage. The success of balloon angioplasty -the first-line standard treatment method for BTK lesions- is adversely affected by flow-limiting dissection and severe calcification. New methods continue to be investigated to improve the outcomes of balloon angioplasty.³

The use of intravascular ultrasound (IVUS) has been deemed appropriate for all stages of endovascular procedures in tibial arteries, including vessel sizing, stenosis severity, and occlusion assessment.⁴ Adding IVUS as an adjunct to conventional angiography in lower limb endovascular interventions improves 1-year patency rates⁵ independently. Although the use of IVUS results in larger lumen measurements and consequently larger balloon sizes compared with angiography alone, balloons ranging from 2 to 3 mm in diameter are still preferred in tibial arteries to avoid vessel injury.^{6,7} In BTK lesions, calcification surrounding the vessel wall is common. Although adjunctive treatments, such as atherectomy, intravascular lithotripsy, and specialty balloons, in addition to balloon angioplasty, can reduce complications and improve outcomes, they also result in increased costs and heterogeneous efficacy.⁸ Although some adjunctive methods to balloon angioplasty in BTK lesions may increase limb salvage, 1-year patency rates remain similar.⁹ It has been noted that increasing balloon lumen size in circumferentially calcified lesions may not carry a high risk of vessel injury.¹⁰ The use of IVUS in lower extremity endovascular interventions significantly reduces the amount of contrast material required.¹¹ In tibial arteries, the use of IVUS is recommended to minimize contrast material usage.⁴

The optimal treatment for calcified BTK lesions remains unclear. In the present study, we aim to achieve effective treatment of challenging calcified BTK lesions by using IVUS to facilitate safe and incremental appropriate balloon sizing, elucidate angioplasty efficacy through changes in lumen area, and minimize contrast material usage. Based on the hypothesis that larger balloons can be used safely and effectively for the endovascular treatment of severely calcified BTK le-

sions with stand-alone balloon angioplasty, the study aims to determine the optimal balloon diameter.

Methods

Study design

This single-center, retrospective study was conducted in accordance with the Declaration of Helsinki after obtaining approval from the Ankara Bilkent City Hospital Institutional Review Board (decision number: TABED 2-24-224, date of approval: May 29, 2024), and informed consent was waived due to the study's retrospective nature. All consecutive patients who underwent IVUS-guided conventional balloon angioplasty for the treatment of severely calcified anterior tibial artery and posterior tibial artery lesions between February 2024 and April 2024 were reviewed. The study population comprised patients presenting with Rutherford category 4–6 and severely calcified lesions causing >70% stenosis on digital subtraction angiography (n = 17) (Figure 1).¹²

Intravascular ultrasound-guided balloon angioplasty procedure

After placing a 5F sheath in the ipsilateral common femoral artery, 70 IU/kg of heparin was injected intra-arterially. A CO₂ angiography from the groin to the ankle was performed. Lesions were crossed using a 0.018-inch guidewire (Gladius; Asahi In-

tecc, Aichi, Japan). The nominal pressure of the 3 and 3.5 mm diameter semi-compliant balloons used over a 0.014-inch guidewire is 6 atm (Minerva, Guangdong, China). The balloons were selected to be 150 or 200 mm in length to cover the target lesions. A 3 mm diameter balloon was inflated at 6–8 atm pressure for 30 seconds in the target tibial artery. In all patients, including those with chronic total occlusion, the first IVUS procedure was performed after 3 mm balloon dilation. Intraluminal imaging was conducted using a 20 MHz Eagle Eye Platinum ST catheter (Philips Volcano, San Diego, USA). Subsequently, a 3.5 mm diameter balloon was inflated at 4–6 atm pressure for 30 seconds. Afterward, intraluminal imaging was repeated with IVUS. At the end of the procedure, pedal arch patency was visualized using iodinated contrast material diluted with saline in a 1:4 ratio. No additional endovascular treatment methods were applied. Patients with wounds continued their medical treatment with a wound care specialist team. In IVUS frames, the minimum lumen area was defined as the area measured in the section with the smallest lumen area in the proximal, mid, and distal segments separately, and the mean diameter in this section was defined as the minimum lumen diameter. IVUS measurements were manually performed on the IVUS device by two radiologists with 20 years and 5 years of experience in consensus. The minimum lumen area and minimum lumen

Main points

- This is the first report demonstrating the effectiveness of gradually increasing balloon size up to 3.5 mm in calcified tibial arteries by measuring the vessel lumen area with intravascular ultrasound (IVUS) before and after the procedure.
- The use of IVUS guidance in this approach almost eliminates the need for contrast material, increasing the safety of the procedure.
- Balloon diameters larger than standard were successfully applied under IVUS guidance, treating tibial arteries effectively from proximal to distal.

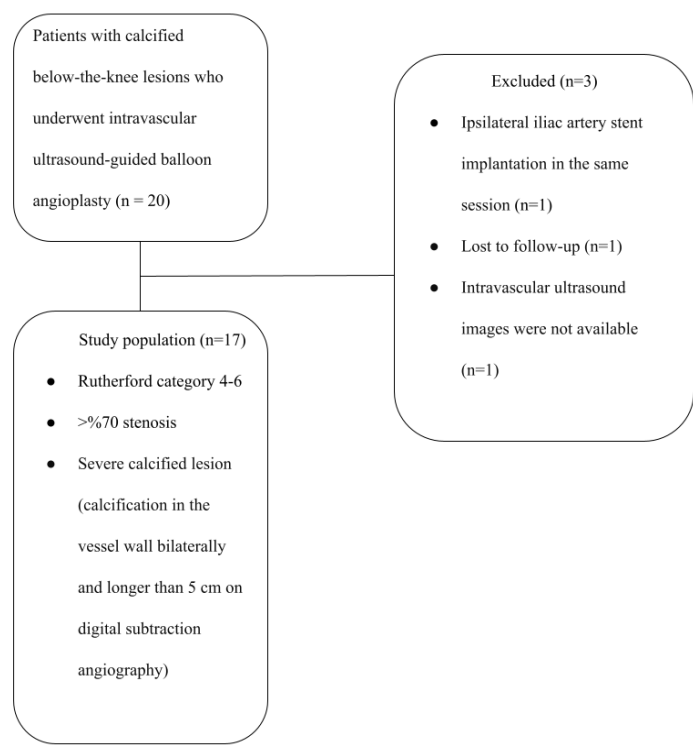


Figure 1. Flowchart of study population selection.

diameter were measured with IVUS before and after 3.5 mm balloon angioplasty in the proximal, mid, and distal segments. Due to the posterior acoustic shadowing created by severe calcifications surrounding the vessel wall, the lumen area was measured by trac-

ing the inner boundary of the calcifications. When manual boundary drawing was performed, the area and diameter values were automatically provided as output (Figures 2-4). The severe calcification prevented the assessment of the internal and external elas-

tic lamina; therefore, the lumen area and diameters were measured based on the inner border of the calcification. The lumen area measured before and after the procedure for the proximal, mid, and distal segments were compared to determine the lumen increase ratio. Thus, the efficacy of the 3.5 mm balloon angioplasty was assessed. In the IVUS images, vessel wall calcification was classified as $\geq 180^\circ$ – $<270^\circ$ or $\geq 270^\circ$ degrees circumferential. In the one- and three-month follow-up imaging, a peak systolic velocity of <200 cm/s in Doppler ultrasound was considered indicative of no significant restenosis.

Statistical analysis

Statistical analyses were performed using SPSS version 26.0 (IBM, IL, USA). The Shapiro–Wilk test was used to determine whether the data followed a normal distribution. Continuous variables were expressed as mean \pm standard deviation and median (range). Comparisons of pre- and post-procedure minimum lumen area and minimum lumen diameter in the proximal, mid, and distal tibial artery segments were performed using Student's t-test. The Kruskal–Wallis test was used to compare the increase in minimum lumen area post-procedure among these three segments. A P value of <0.05 was considered statistically significant.

Results

Baseline characteristics

In the study population of 17 patients (88.2% male, mean age 67.9 ± 8 years), the mean follow-up duration was 134.1 ± 12 days (Table 1). All lesions were classified as category D according to the Trans-Atlantic Inter-Society Consensus classification.

Procedural details

No complications, such as flow-limiting dissection, distal embolization, or vascular perforation, were observed during the procedure. IVUS revealed that 61.9% of the arteries had circumferential calcification of $\geq 270^\circ$. Significant increases in lumen diameter ($P < 0.001$ for all) and lumen area ($P < 0.001$, $P = 0.003$, $P = 0.002$, respectively) were observed in the proximal, mid, and distal segments of the BTK arteries following IVUS-guided 3.5 mm balloon angioplasty (Table 2). Mean lumen diameters of the BTK arteries in the proximal, mid, and distal segments following IVUS-guided 3.5 mm balloon angioplasty increased by 0.47 mm, 0.53 mm, and 0.45 mm, respectively. However, there were no signif-

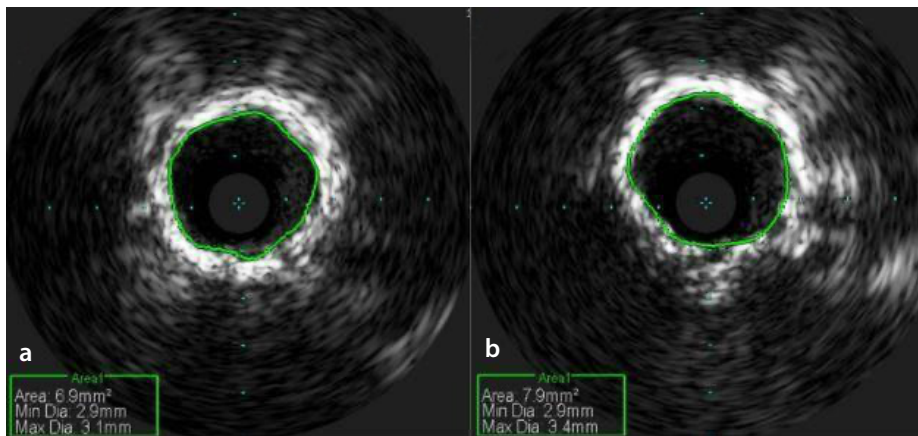


Figure 2. Measurement of minimum lumen diameter and area in intravascular ultrasound analysis of the calcified lesion in the proximal segment of the posterior tibial artery before (a) and after (b) 3.5 mm balloon angioplasty.

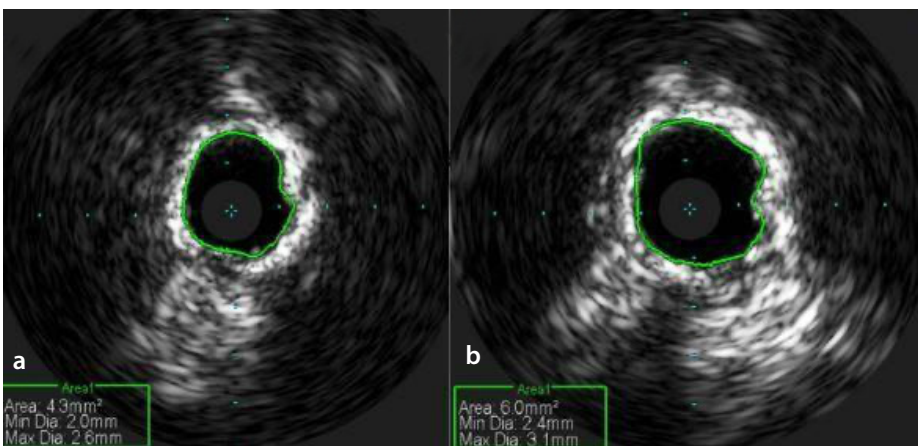


Figure 3. Measurement of minimum lumen diameter and area in intravascular ultrasound analysis of the calcified lesion in the mid segment of the posterior tibial artery before (a) and after (b) 3.5 mm balloon angioplasty.

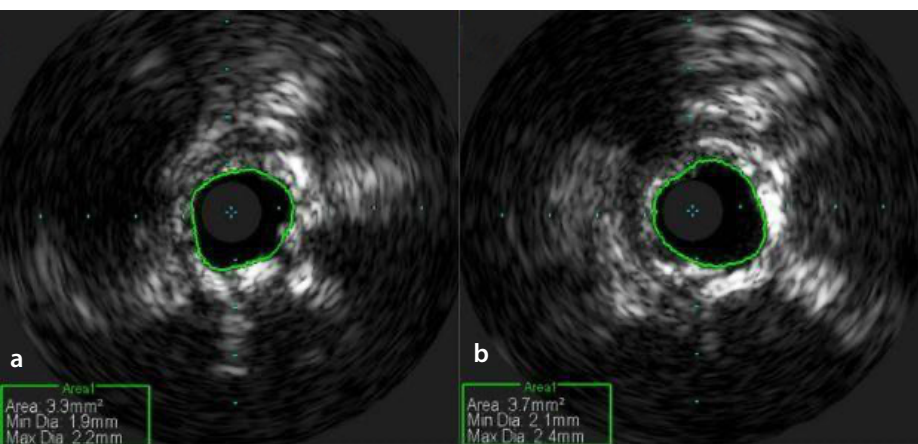


Figure 4. Measurement of minimum lumen diameter and area in intravascular ultrasound analysis of the calcified lesion in the distal segment of the posterior tibial artery before (a) and after (b) 3.5 mm balloon angioplasty.

Age (years)	67.9 ± 8
Gender (male)	15 (88.2)
Hypertension	9 (52.9)
Diabetes mellitus	13 (76.5)
Chronic kidney disease	2 (11.8)
Coronary artery disease	9 (52.9)
Cerebrovascular ischemic event	2 (11.8)
Dyslipidemia	9 (52.9)
Smoking history (pack-years)	30 (range, 0–70)
Current smoker	5 (29.4)
Rutherford category 5/6	8 (47.1)
Chronic total occlusion	9 (42.9)
Lesion length (mm)	209 ± 44
Lesion location	
Posterior tibial artery	9 (42.9)
Anterior tibial artery	12 (57.1)
Procedure time (min)	44.1 ± 11.5

Variables are presented as mean ± standard deviation and number (percentage).

	Pre-procedure	Post-procedure	P value
Proximal			
Minimum lumen diameter (mm)	2.78 ± 0.42	3.25 ± 0.34	<0.001
Minimum lumen area (mm ²)	5.99 ± 1.79	8.16 ± 1.59	<0.001
Mid			
Minimum lumen diameter (mm)	2.32 ± 0.29	2.85 ± 0.40	<0.001
Minimum lumen area (mm ²)	4.21 ± 1.06	6.39 ± 1.87	0.003
Distal			
Minimum lumen diameter (mm)	2.16 ± 0.24	2.61 ± 0.37	<0.001
Minimum lumen area (mm ²)	3.56 ± 0.83	5.26 ± 1.46	0.002

Values are presented as mean ± standard deviation.

follow-up showed high patency rates, satisfactory wound healing, and effective limb salvage.

In studies investigating the efficacy of balloon angioplasty in BTK lesions under IVUS guidance, the rate of severe calcification in tibial arteries ranges from 60% to 90%.^{6,7} Fujihara et al.¹³ defined severe calcification as $\geq 180^\circ$ in the superficial femoral artery using IVUS. In this study, all selected lesions were already severely calcified according to digital subtraction angiography, and all had $\geq 180^\circ$ calcification on IVUS. Moreover, vessel wall calcification was more severe in three out of five patients, reaching $\geq 270^\circ$. The increased complexity of calcified lesions has led to the use of various methods, such as atherectomy, intravascular lithotripsy, and specialty balloons; however, study results are highly heterogeneous, and there is no demonstrated superiority over stand-alone balloon angioplasty.^{9,14} Modifications to balloon angioplasty techniques, including incremental balloon oversizing, are also being explored. If balloon diameter oversizing is to be performed, a gradual approach is recommended to avoid flow-limiting dissection due to excessive stretching.⁸ Balloon oversizing can lead to significant dissection in lesions with spotty calcification, whereas in circumferentially calcified lesions, it shows limited dissection and maximizes lumen gain.¹⁰ Peripheral vascular procedures are safer with IVUS use and reduce the risk of vascular complications.¹⁵ IVUS has shown that tibial artery diameters are larger compared with angiographic assessment, thus avoiding the use of undersized balloons and suboptimal lumen gain.¹⁶ However, even in IVUS-guided studies, balloons typically in the 2–3 mm diameter range are preferred due to the risk of vessel injury.^{6,7} Normal tibial artery diameters in men aged >60 years are approximately 3–3.5 mm and can exceed 4 mm.¹⁷ In an IVUS study, the mean diameter of the proximal and distal segments of BTK arteries was found to be 4 ± 1 mm.¹⁶ In light of these findings, a luminal diameter of ≥ 3 mm was targeted, aiming for resolution by increasing the balloon diameter. In the current study, the mean lumen diameter did not reach 3 mm with 3 mm balloon angioplasty, but significant lumen area expansion was achieved without complications after 3.5 mm balloon angioplasty. Following 3 mm balloon angioplasty, an IVUS assessment revealed that the minimum luminal diameters in all segments remained below even the targeted minimum value of 3 mm, leading to the use of a 3.5 mm

icant differences in the lumen area increase ratios among the proximal, mid, and distal segments ($P = 0.905$). Iodinated contrast material was only used for visualizing the pedal arch at the end of the procedure (median 2 mL; range 1–4 mL). The pedal arch was patent in all patients.

Follow-up outcomes

Foot ulcers were present in 47.1% of the patients, and 62.5% of these wounds healed completely during the short-term follow-up. All patients in Rutherford category 4 showed an improvement of ≥ 1 point. At the 4th month post-procedure, in a patient who experienced an increase in wound severity, the target vessel remained patent, but the occluded stents in the superficial femoral artery and external iliac artery were recan-

alized endovascularly. During the follow-up period, no restenosis, target vessel revascularization, or amputation was observed. Follow-up Doppler ultrasounds confirmed that all target vessels remained patent. No cases of contrast-induced nephropathy were observed.

Discussion

In the endovascular treatment of calcified BTK lesions with balloon angioplasty, determining the optimal balloon diameter to prevent vascular complications is a primary focus. In severely calcified lesions of the anterior tibial artery and posterior tibial artery, sequential balloon angioplasty with 3 mm and then 3.5 mm diameters under IVUS guidance achieved better lumen expansion without vascular complications. Short-term

balloon. Significant lumen enlargement was achieved in all segments of calcified tibial arteries with IVUS-guided incremental balloon oversizing. Effective and safe treatment was provided with balloon angioplasty as the primary treatment method without the need for additional cost-incurring methods. The rate of lumen enlargement provided by balloon angioplasty was similar in the proximal, mid, and distal segments. This indicates the applicability of the 3.5 mm oversized balloon to all segments and is beneficial for procedural simplicity by using the same balloon.

In the clinical research conducted by Brahmandam et al.⁵, the 1-year patency rate in lower limb peripheral artery interventions, particularly in groups with chronic limb-threatening ischemia, long segment lesions, multiple stenoses/occlusions, or severe calcification, was positively impacted by IVUS assistance, exceeding 97%. In a similar current study population with severely calcified lesions, characterized by an average lesion length >20 cm and nearly half having chronic total occlusions, all target vessels remained patent at the short-term follow-up. A meta-analysis examining the mid-term effects of IVUS guidance in lower extremity peripheral artery disease endovascular interventions demonstrated a reduction in major amputation rates. However, it did not show a significant reduction in target lesion revascularization and mortality.¹⁸ IVUS-guided endovascular intervention for BTK lesions positively influences wound healing and can reduce the healing period from 4–5 months to 3 months. The wound healing rate was observed to be approximately 60% by the 3rd–4th month of follow-up.^{6,7} In this study, no mortality was observed in the short-term follow-up, and there was no need for target vessel revascularization or major amputation. Similarly, wound healing of >60% was observed during a mean follow-up of 4 months. Although short-term results are favorable, mid- and long-term follow-up is necessary.

Stenotic and occlusive disease of the tibial arteries is frequently seen in patients who are diabetic, and renal dysfunction is among the relative contraindications for endovascular procedures.¹⁹ Although CO₂ angiography is successfully applied in above-the-knee arteries, it is not sufficient alone at the BTK level due to fragmentation and overestimation of stenosis degree.²⁰ Studies on BTK balloon angioplasty treatments have reported the use of an average of 60–130 mL of iodinated contrast material.^{7,21} The use of IVUS can help

mitigate these issues by reducing iodinated contrast material usage. In the current study population, where three out of four patients were diabetic, the use of IVUS-guided ultra-low contrast material (median 2 mL) completely avoided the risk of contrast nephropathy and preserved renal function, which is of great value.

The study has some limitations. It is a single-center, retrospective study with a small population size. Furthermore, there was no control group. Nominal pressure was used for inflation in all balloon angioplasties; therefore, the impact of high-pressure inflation on the outcomes could not be assessed. Due to the relatively short follow-up period, mid- and long-term follow-up results could not be presented; however, this does not affect the reporting of the primary outcomes of the study, such as complications and lumen gain. Selection bias is inevitable as the approach targets the severely calcified lesion group. Advancing the IVUS catheter in narrow lumens can be challenging; however, as the initial IVUS imaging in all cases was performed after 3 mm balloon angioplasty, no such issue was encountered. Although IVUS imaging inevitably extends the procedure time, no specific duration was measured for this in the study. To the best of our knowledge, this study is the first report to demonstrate the effectiveness of a gradual balloon size increase up to 3.5 mm in diameter by measuring the vessel lumen area before and after the procedure in calcified tibial arteries, almost eliminating the use of contrast material with IVUS guidance. Balloon diameters above the standard were used effectively and successfully with IVUS guidance from the proximal to the distal tibial arteries. In the future, randomized controlled multicenter prospective long-term follow-up studies will be beneficial for determining the optimal lumen diameter increase in IVUS-guided interventions for calcified BTK lesions and for standardizing the appropriate treatment approach.

In conclusion, the search for the optimal treatment of calcified BTK lesions is ongoing. Gradual balloon diameter increase up to 3.5 mm under IVUS guidance in calcified BTK lesions has demonstrated effectiveness and success by providing ultra-low contrast usage, low complication rates, high patency, and high limb salvage rates in short-term follow-up, along with satisfactory wound healing.

Footnotes

Conflict of interest disclosure

The authors declared no conflicts of interest.

References

1. Shu J, Santulli G. Update on peripheral artery disease: epidemiology and evidence-based facts. *Atherosclerosis*. 2018;275:379-381. [\[CrossRef\]](#)
2. Kwong M, Rajasekar G, Utter GH, Nuño M, Mell MW. Updated estimates for the burden of chronic limb-threatening ischemia in the Medicare population. *J Vasc Surg*. 2023;77(6):1760-1775. [\[CrossRef\]](#)
3. Li J, Varcoe R, Manzi M, et al. Below-the-knee endovascular revascularization: a position statement. *JACC Cardiovasc Interv*. 2024;17(5):589-607. [\[CrossRef\]](#)
4. Secemsky EA, Aronow HD, Kwolek CJ, et al. Intravascular ultrasound use in peripheral arterial and deep venous interventions: multidisciplinary expert opinion from SCAI/AVF/AVLS/SIR/SVM/SVS. *J Vasc Interv Radiol*. 2024;35(3):335-348. [\[CrossRef\]](#)
5. Brahmandam A, Kim TI, Parziale S, et al. Intravascular ultrasound use is associated with improved patency in lower extremity peripheral arterial interventions. *Ann Vasc Surg*. 2024;106:410-418. [\[CrossRef\]](#)
6. Soga Y, Takahara M, Ito N, et al. Clinical impact of intravascular ultrasound-guided balloon angioplasty in patients with chronic limb threatening ischemia for isolated infrapopliteal lesion. *Catheter Cardiovasc Interv*. 2021;97(3):376-384. [\[CrossRef\]](#)
7. Fujihara M, Yazu Y, Takahara M. Intravascular ultrasound-guided interventions for below-the-knee disease in patients with chronic limb-threatening ischemia. *J Endovasc Ther*. 2020;27(4):565-574. [\[CrossRef\]](#)
8. Giannopoulos S, Varcoe RL, Lichtenberg M, et al. Balloon angioplasty of infrapopliteal arteries: a systematic review and proposed algorithm for optimal endovascular therapy. *J Endovasc Ther*. 2020;27(4):547-564. [\[CrossRef\]](#)
9. Nugteren MJ, Welling RHA, Bakker OJ, Ünlü Ç, Hazenberg CEVB. Vessel preparation in infrapopliteal arterial disease: a systematic review and meta-analysis. *J Endovasc Ther*. 2024;31(2):191-202. [\[CrossRef\]](#)
10. Welling RHA, de Borst GJ, van den Heuvel DAF, et al. Vessel calcification patterns should determine optimal balloon size strategy in below the knee angioplasty procedures. *Eur J Vasc Endovasc Surg*. 2020;60(4):636-637. [\[CrossRef\]](#)
11. Pesonen LO, Knol MC, Shelgikar CS, Battaglia MA, Heidenreich MJ, Aziz A. Efficacy and utilization of intravascular ultrasound in

- office-based lower extremity endovascular interventions for peripheral arterial disease. *Vascular*. 2024;32(1):57-64. [\[CrossRef\]](#)
12. Rocha-Singh KJ, Zeller T, Jaff MR. Peripheral arterial calcification: prevalence, mechanism, detection, and clinical implications. *Catheter Cardiovasc Interv*. 2014;83(6):212-220. [\[CrossRef\]](#)
 13. Fujihara M, Kozuki A, Tsubakimoto Y, et al. Lumen gain after endovascular therapy in calcified superficial femoral artery occlusive disease assessed by intravascular ultrasound (CODE Study). *J Endovasc Ther*. 2019;26(3):322-330. [\[CrossRef\]](#)
 14. Benfor B, Sinha K, Lumsden AB, Roy TL. Scoping review of atherectomy and intravascular lithotripsy with or without balloon angioplasty in below-the-knee lesions. *J Vasc Surg Cases Innov Tech*. 2023;9(2):101185. [\[CrossRef\]](#)
 15. Sheikh AB, Anantha-Narayanan M, Smolderen KG, et al. Utility of intravascular ultrasound in peripheral vascular interventions: systematic review and meta-analysis. *Vasc Endovascular Surg*. 2020;54(5):413-422. [\[CrossRef\]](#)
 16. Shammam NW, Shammam WJ, Jones-Miller S, et al. Optimal vessel sizing and understanding dissections in infrapopliteal interventions: data from the idissection below the knee study. *J Endovasc Ther*. 2020;27(4):575-580. [\[CrossRef\]](#)
 17. Lorbeer R, Grotz A, Dörr M, et al. Reference values of vessel diameters, stenosis prevalence, and arterial variations of the lower limb arteries in a male population sample using contrast-enhanced MR angiography. *PLoS One*. 2018;13(6):0197559. [\[CrossRef\]](#)
 18. Tsukagoshi J, Shimoda T, Yokoyama Y, et al. The mid-term effect of intravascular ultrasound on endovascular interventions for lower extremity peripheral arterial disease: a systematic review and meta-analysis. *J Vasc Surg*. 2024;79(4):963-972. [\[CrossRef\]](#)
 19. Spiliopoulos S, Del Giudice C, Manzi M, Reppas L, Rodt T, Uberoi R. CIRSE standards of practice on below-the-knee revascularisation. *Cardiovasc Intervent Radiol*. 2021;44(9):1309-1322. [\[CrossRef\]](#)
 20. Taha AG, Saleh M, Ali H. Safety and efficacy of hybrid angiography in chronic lower extremity ischemia patients at risk of contrast-induced acute kidney injury. *Vasc Endovascular Surg*. 2022;56(2):180-189. [\[CrossRef\]](#)
 21. Del Giudice C, Gandini R. Six-month angiographic and clinical outcomes of therapeutic ultrasound pretreatment associated with plain balloon angioplasty for below-the-knee lesions in patients with critical limb ischemia: a prospective, single-center pilot study. *J Endovasc Ther*. 2019;26(2):191-198. [\[CrossRef\]](#)